



Original Full Paper

Isolation, Characterization and Pathology of *Citrobacter freundii* Infection in Native Brazilian Catfish *Pseudoplatystoma*

Santiago Benites de Pádua^{1*}, Debora Peixoto Marques², Fernanda Alexandre Sebastião³, Fabiana Pilarski³, Maurício Laterça Martins⁴, Márcia Mayumi Ishikawa⁵

¹AQUIVET Saúde Aquática, Rua Cristóvão Colombo, 1519, Jardim Nazareth, 15054-000, São José do Rio Preto, São Paulo, Brazil

²Anhanguera Faculty of Dourados, Rua Manoel Santiago, 1155, 79825-150, Dourados, MS, Brazil.

³LAPOA - Laboratory of Aquatic Organisms Pathology, Aquaculture Center of São Paulo State University (CAUNESP), Via de Acesso Prof. Paulo Donato Castellane s/n, 14884-900, Jaboticabal, SP, Brazil

⁴AQUOS - Aquatic Organisms Health Laboratory, Aquaculture Department, Federal University of Santa Catarina (UFSC), Rod. Admar Gonzaga 1346, 88034-000, Florianópolis, SC, Brazil

⁵Embrapa Environment, Rod. SP 340, km 127,5 13820-000, Jaguariúna, SP, Brazil

*Corresponding author: E-mail: santiago@aquivet.com.br

Submitted August 23th 2014, Accepted November 04th 2014

Abstract

Bacterial diseases are responsible for important economic losses in aquaculture over the world, and South American catfishes are susceptible to Gram negative bacteria causative of haemorrhagic septicemia. This study registers the biochemical characteristics, antimicrobial resistance and pathological effects of *Citrobacter freundii* infection in cachara *Pseudoplatystoma reticulatum*. Moribund juvenile fish with non-specific clinical signs were used for bacteriological and parasitological diagnosis. No parasitic infections were found in examined fish, but two isolate obtained from the kidney and encephalon was characterized by Gram negative bacilli, catalase positive and oxidase negative. Isolates were submitted to biochemical identification by a commercial API 20E. Susceptibility analysis to 15 drugs was performed by the diffusion method in Agar Muller Hinton discs. Experimental assay was also made to confirm the Kock postulate. The isolates showed biochemical profile corresponding to *Citrobacter freundii*. A multiresistance at 66.7% of the antibiotic molecules tested was observed. In experimental infection haemorrhagic septicaemia, severe enteritis and important lesions in kidney and gills are described.

Key words: Siluriformes, Enterobacteriaceae, hemorrhagic septicaemia, antimicrobial resistance.

Introduction

Citrobacter freundii belongs to Enterobacteriaceae family comprehending Gram negative bacilli, catalase positive and oxidase negative organisms. It is an important infectious agent recognized as opportunistic pathogen in medical and veterinary science (6, 26), responsible for systemic hemorrhages and gastroenteritis in animals (1) and human patients (21). In contrast, other clinical manifestations were related in a patient that manipulated Nile tilapia *Oreochromis niloticus* leading to necrotizing fasciitis and osteomyelitis (6).

Bacteriosis in fish has a worldwide distribution being reported in Europe (1, 12), Meridional Asia (13), Oriental Asia (2, 14, 22) and North America (17). In general, the infection caused by *C. freundii* is related to high water temperature periods, low environmental quality, stress factors that compromise the organic defense of animals (1, 2, 13). It may appear as an acute form with marked and rapid mortality (2) or in a chronic form with lower and progressive mortality (1).

Production of native South American catfish is an emergent activity in Central Brazil (19). Among the farmed species, *Pseudoplatystoma* genus is among one of

the most cultured (4). Nevertheless, sanitary aspects in the catfish production are still barely known and bacterial infections are responsible for significant economic losses in fish farms (5, 24). Currently, reports on characterization of bacterial pathogens that impact the catfish production are scarce.

Most of the investigators have focused on the occurrence of *Plesiomonas shigelloides* and *Staphylococcus* sp. (7), *Pseudomonas* sp. (25), *Lactococcus garvieae* and *Streptococcus* sp. (9), Anaplasmataceae-like (11) and *Aeromonas hydrophila* (24). These reports were restricted to "pintado" (*Pseudoplatystoma corruscans*) and the hybrid "surubim" (*P. corruscans* male x *P. reticulatum* female) with no registers on the native "cachara" (*P. reticulatum*).

To the best of our knowledge, this study describes by the first report of *C. freundii* infection in *P. reticulatum*, including the biochemical profile, antimicrobial susceptibility to 15 drugs and pathogenicity.

Material and Methods

Fish

A total of 200 apparently healthy fish measuring 20.0 ± 2.1 cm from a commercial fish farm located in the municipality of Terenos, Mato Grosso do Sul, Central part of Brazil were transported to the Fish Farming Laboratory of Embrapa Agropecuária Oeste, in Dourados Brazil. They were acclimatized in circular tanks 1,000 L tanks with a constant flow of water from artesian well (10 L min^{-1}) and fed commercial extruded diet (45% crude protein).

Mortality and etiological agent

During the acclimation period, some fish showed anorexia, darkened skin, erratic swimming, skin lesions and the mortality was recorded. Moribund fish were handled for preparation of skin, fins and gill scrapes to detect parasites. The fish were euthanized with clove oil (100 mg L^{-1}) according to the ethic procedures in the animal use (PP00928 CEUA/UFSC). Fish were externally washed with water and neutral detergent, disinfected with iodate-alcohol and submitted to renal and brain sampling for bacterial isolation using the culture medium BHI (Brain heart infusion, Merck) for fastidious microorganisms according to (20).

Isolates were submitted to Gram staining, oxidase and catalase test, and biochemical identification using a commercial kit API 20E (BioMérieux, France), according to the manufacturer orientations.

Susceptibility test to antimicrobials

Antimicrobial susceptibility was assessed by a diffusion method in Agar Muller Hinton (NCCLS, 2004) discs. Polidisc racks containing 15 antimicrobials (DME,

Brazil) were used. Antimicrobial included Ampicillin (AMP), Gentamicin (GEN), Cefalotin (CFL), Ciprofloxacin (CIP), Sulfazotrin (SUT), Amoxylin/clavulanic acid (AMC), Ceftriaxone (CRO), Tetracycline (TET), Penicillin (PEN), Oxacilin (OXA), Erythromycin (ERI), Vancomycin (VAN), Clindamycin (CLI), Rifampicin (RIF) e Cloranfenicol (CLO). The sensitivity and resistance of isolate bacterium as well as the diameter of inhibition were determined according to the manufacturer orientation.

Experimental infection

To fulfill Kock's postulate, 14 fish weighing $1,050.0 \pm 150.5$ g and measuring 51.8 ± 7.2 cm, with no clinical signs of disease, distributed in two circular 1,000 L tanks, with a constant flow of water from an artesian well (10 L min^{-1}) were fed commercial extruded diet with 35% crude protein.

Water quality was kept within a comfort range for the species, as follows: water temperature ($25.2 \pm 0.3^\circ\text{C}$) and dissolved oxygen ($5.1 \pm 0.3 \text{ mg L}^{-1}$) were measured using a multiparameter (YSI® 55, Incorporated, Yellow Spring, EUA). Daily, the bottom of the tanks was cleaned by siphon to remove organic residues.

After fish euthanasia, the isolate of *C. freundii* was inoculated in BHI broth incubated at 25°C during 24 h. Bacterial suspension was then centrifuged ($3,000 \text{ g}$ for 10 min), washed three times with sterile phosphate-buffered saline (PBS) and suspended in the same solution. Seven fish anesthetized in a clove oil solution (75 mg L^{-1}) were intraperitoneally inoculated with 1.0×10^8 colony forming units (CFU)/ mL^{-1} diluted in 0.7 mL, and the other ones were inoculated with 0.7 mL PBS (control). After challenge, the fish were monitored five times a day for the presence of any clinical signs and/or mortality for a period of 15 days. Dead fish were necropsied for microbiological analysis and fragments of the encephalon, liver, kidney, heart, spleen and gills were collected and fixed in 10% buffered formalin solution. The material was processed according to usual histologic techniques to obtain $5 \mu\text{m}$ sections that were stained with hematoxylin and eosin. Slide analysis and the photomicrographs were made using a microscope Nikon E200® equipped with a capture image system Moticam 2300®.

Results

Detection of the etiological agent

Moribund fish had non-specific clinical signs such as anorexia, darkened skin and erratic swimming. Some fish had hemorrhagic and ulcerative skin lesions. No ectoparasites were observed in diseased fish. Two isolates obtained from fish kidneys and encephalon were characterized by Gram negative bacilli, colonies of convex morphology of 2-4 mm diameter and orange-brown in

Table 1. Biochemical features of *Citrobacter freundii* isolated from native Brazilian catfish *Pseudoplatystoma reticulatum*.

Reaction	Abbreviation	Isolate 1	Isolate 2
2-nitrophenyl-βD-galactopyranoside	ONPG	+	+
L-arginine	ADH	+	+
L-lysine	LDC	-	-
L-ornithine	ODC	-	-
Trisodium citrate	CIT	+	+
Sodium thiosulphate	H ₂ S	+	+
Urea	URE	-	-
L-tryptophane	TDA	-	-
L-tryptophane	IND	-	-
Sodium pyruvate	VP	-	-
Gelatinase	GEL	-	+
D-glucose	GLU	+	+
D-mannitol	MAN	+	+
Inositol	INO	-	-
D-sorbitol	SOR	+	+
L-rhamnose	RHA	+	+
D-sucrose	SAC	+	+
D-melibiose	MEL	+	+
Amygdalin	AMY	-	+
L-arabinose	ARA	+	+
Oxidase	OX	-	-
Catalase	CAT	+	+

color. Isolates were identified as *C. freundii* with 99.9% probability (Table 1).

Susceptibility to antimicrobials

It was observed a multi-resistant characteristic of *C. freundii* to antimicrobials being sensitive to only 33.3% of the drugs tested. Isolates were sensitive to gentamicin, ciprofloxacin, sulfazotrim, tetracyclin and cloranfenicol (Table 2).

Experimental infection

Fish experimentally infected with an isolated strain of *C. freundii* had darkened skin and hyporexia at 24 h after inoculation. Ninety six hours after challenge, 12.5% mortality was recorded. Grossly, few hemorrhagic petechiae in the abdomen and caudal fin with discrete fin erosion (Fig. 1 a-b) were observed. Internally, peritonitis with multifocal to coalescent hemorrhagic petechiae on the mesentery and peritoneum were observed (Fig. 1 c).

Diffuse hemorrhage was also observed in the encephalon (Fig. 1 d), as well as the occurrence of hemopericardium (Fig. 1 e) and multifocal hemorrhagic

petechiae on the gills (Fig. 1 f). Intestines had edema and hemorrhages (Fig. 1 g), with bloody content of fetid smell (Fig. 1 h).

Table 2. Antimicrobial susceptibility analysis of *Citrobacter freundii* isolates from native Brazilian catfish *Pseudoplatystoma reticulatum*. R: Resistant; S: sensitive.

Antimicrobials (μg)	<i>C. freundii</i>	Antimicrobials (μg)	<i>C. freundii</i>
Ampicillin (10)	R	Penicillin (10)	R
Gentamicin (10)	S	Oxacilin (01)	R
Cefalotin (30)	R	Erythromycin (15)	R
Ciprofloxacin (05)	S	Vancomycin (30)	R
Sulfazotrim (25)	S	Clindamycin (02)	R
Amo/clavulânico acid (20/10)	R	Rifampicin (05)	R
Ceftriaxone (30)	R	Cloranfenicol (30)	S
Tetracyclin (30)	S	-	-

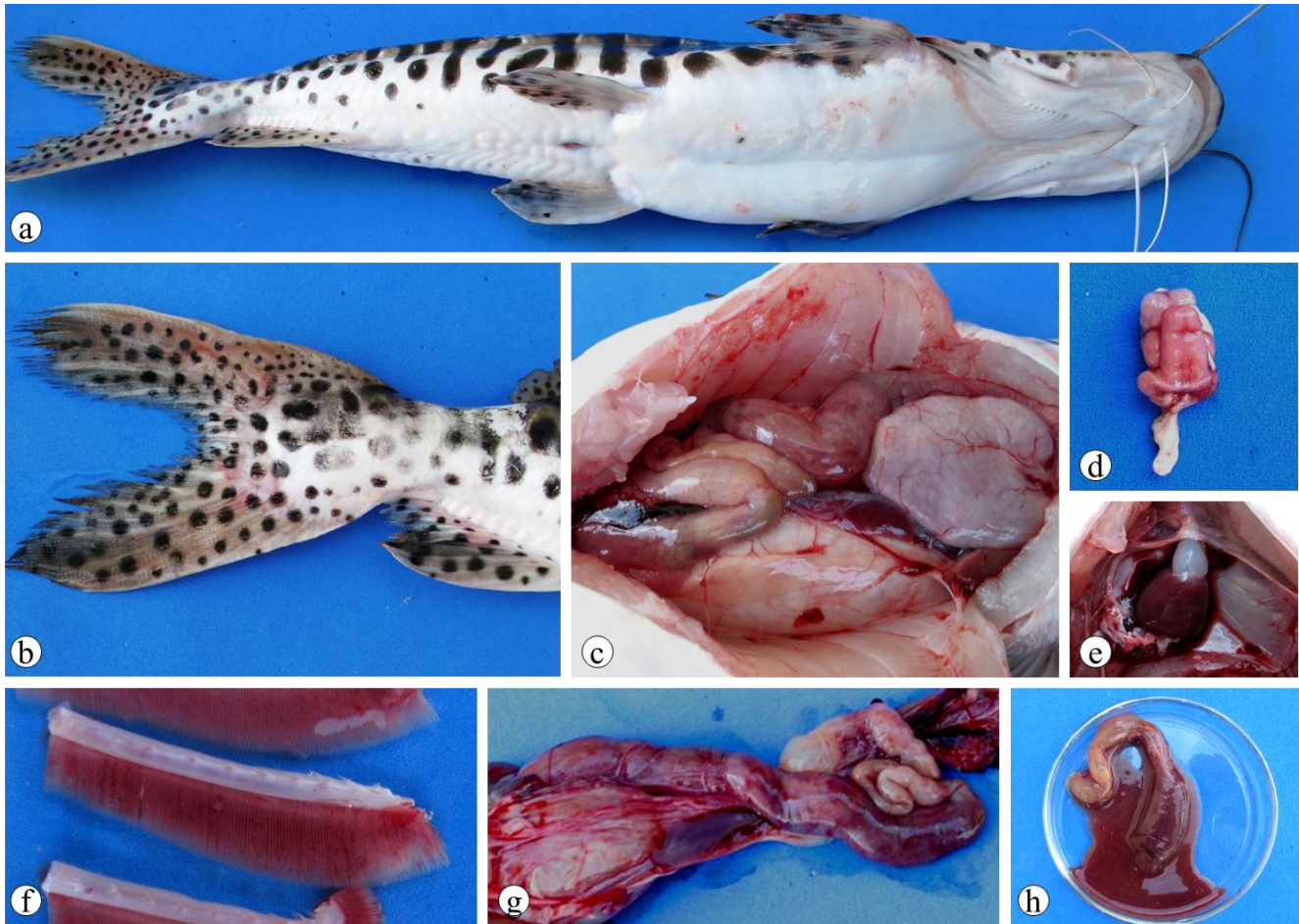


Figure 1. Gross pathology of *Pseudoplatystoma reticulatum* experimentally infected with *Citrobacter freundii* 96 h after infection. Petechial hemorrhage in the abdomen (a - arrows) and caudal fin (b), discrete fin erosion (b), peritonitis with multifocal hemorrhagic foci to coalescents on the mesentery and peritoneum (c), diffuse hemorrhage in the encephalon (d), hemopericardium (e), petechial hemorrhages on the gills (f), edematous and hemorrhagic intestine (g) with bloody content (h).

Histopathological analysis

Severe interstitial hemorrhages in the kidney and gills were the main histological alterations observed. Degeneration and tubular necrosis associated with acidophilic substance in tubular lumen, coagulative necrosis and fibrin deposition was found (Fig. 2a-d). Severe hydropic degeneration with centrilobular necrosis was observed in liver (Fig. 2e). In addition, the gills had hydropic degeneration with focal points of coagulate necrosis, mononuclear infiltrate, interstitial oedema, ulceration, cellular desquamation and telangiectasia (Fig. 2f). The atrium had inflammatory foci, hemorrhages and coagulative necrosis whereas in the encephalon haemorrhages and congestion were the most important changes observed in the encephalon.

Discussion

Citrobacter freundii, an opportunistic pathogen of wide spectrum in susceptible hosts is described by the first time in South American catfish in this study. This important disease causes a generalized infection with hemorrhagic gastroenteritis that has been reported in sunfish *Mola mola* (22), rainbow trout *Oncorhynchus mykiss* (1), carp *Cyprinus carpio* (13), doctor fish *Garra rufa obtusa* (2) and cachara *P. reticulatum* as here described. Apart from its importance in fish, *C. freundii* can cause infections in crustaceans (23), amphibians (15), reptiles (18), birds (26) and mammals (6) resulting in gastrointestinal disease.

The biochemical profile of the isolates was similar to that previously described (1, 12, 13), but some proofs showed positive and negative reactions to gelatinase and amygdaline. Similarly, isolates from rainbow trout also showed variations in the activity of arginine dihydrolase, ornithine decarboxylase, sucrose and rhamnose

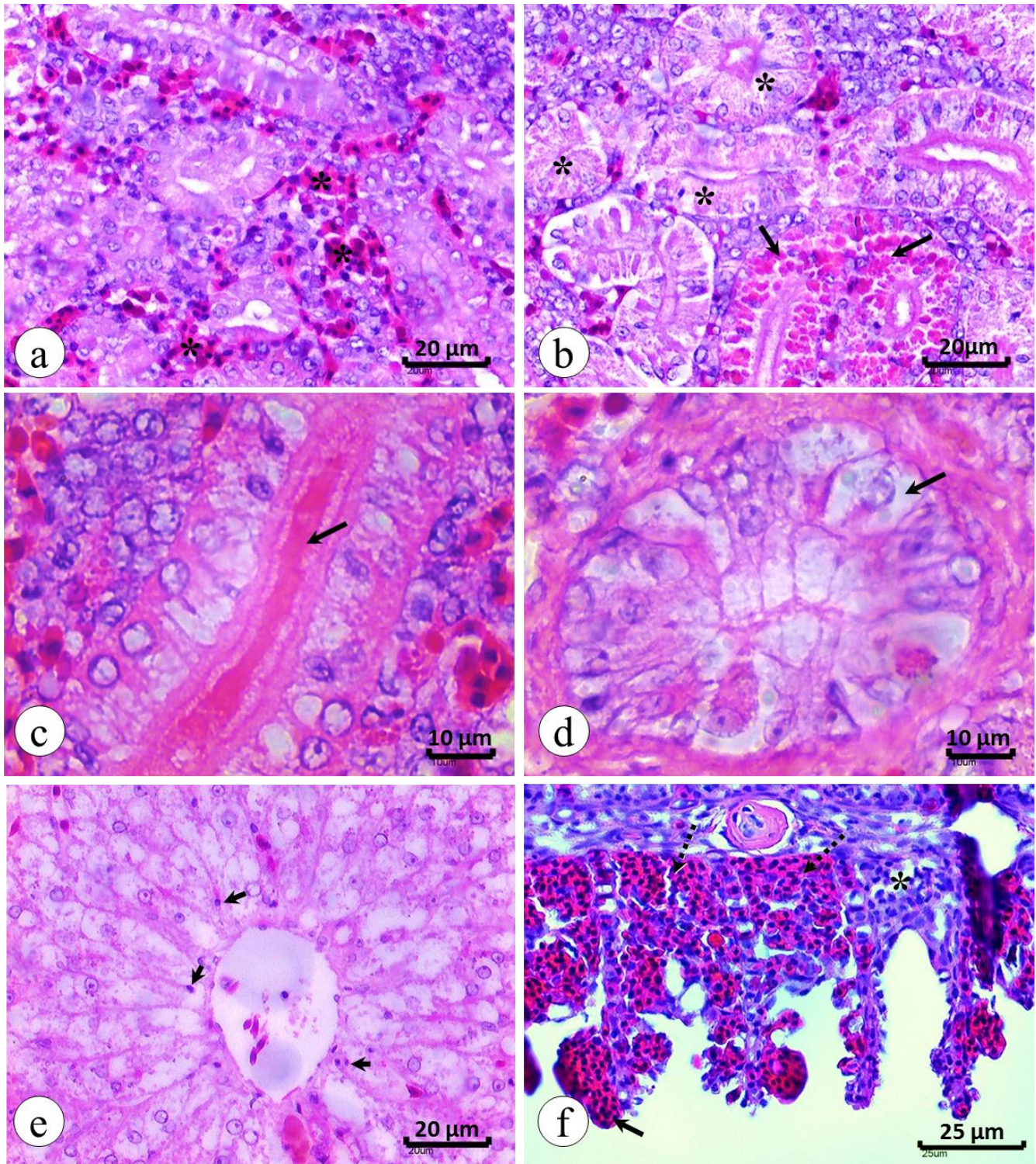


Figure 2. Histopathology of *Pseudoplatystoma reticulatum* experimentally infected by *Citrobacter freundii*. Interstitial haemorrhage in kidney (a), hydropic degeneration (b – asterisks) and hyaline degeneration (b – arrow), with presence of acidophilic substance in tubular lumen (c - arrow) and detailed hydropic degeneration of the renal tubule in transversal section (d - arrow). Liver exhibiting centrilobular necrosis (e - arrow). Gills with interstitial haemorrhage (f – arrowheads) and telangiectasia (f - solid arrows), interstitial oedema (f - asterisk). Stained by haematoxylin-eosin.

fermentation (1, 12, 13) as here observed for gelatinase and amygdaline. Variable biochemical profiles have been previously reported in isolates from different hosts (26). Despite the fact these alterations, the biochemical tests by the API 20E kit were in agreement with bacterial identification (1, 26).

The bacterial multiresistance is one of the most important problems concerning bacteria of medical importance like *C. freundii*. Bacterial multiresistance was also related in farmed fish *Piaractus mesopotamicus* and Nile tilapia (8). It has been demonstrated resistant genes to tetracycline identified in bacteria isolated from fish farms among them *Citrobacter* sp. (10). Indeed, *C. freundii* was isolated from fish resistant to tetracycline and oxytetracycline as the drugs usually applied in aquaculture (26). Once more, it has been reported high prevalence of *Tet*^r genes in isolates from the intestines of farmed North American catfish to the great majority of molecules tested (17), but in this case no resistance of *C. freundii* was found to tetracycline.

Clinical signs and pathological changes observed in this study were similar to those previously described (1, 2, 12, 13). The main clinical manifestations are related to hemorrhagic enteritis and hemorrhages. Diffuse hemorrhage in the encephalon and hemopericardium have not been previously associated with *C. freundii* infection. Similar lesions were reported in hybrid surubim (*P. corruscans* x *P. fasciatum*) infected with *A. hydrophila* (24). Bacterial hemolytic toxins may cause endothelium lesion leading to hemorrhage. Recent studies infer that virulence of this bacterium could be associated with adherence to the gastrointestinal mucosa and cytotoxicity (3).

It seems that not much is known about the overall prevalence and transmission of this disease in fish. Unfortunately, treatment is usually unsatisfactory and historically the recommendation has been to destroy the infected fish. Data collected here indicate that handling management might be strongly associated to disease occurrence. In this study, we have proven the pathogenicity of *C. freundii* in silurid fish farming, and especial care must be spent to apply the best management practices and immunoprophylaxis to improve the fish production and health.

Conclusion

This is the first report of *Citrobacter freundii* in native Brazilian freshwater fish cachara, *Pseudoplatystoma reticulatum*. The disease was characterized by hemorrhages and severe enteritis. The isolates had multiresistance to the majority of antimicrobial tested, representing clinical importance not only to silurid fish culture, but also by the risk of circulation among different hosts.

Acknowledgements

The authors thank National Council of Scientific and Technological Development (CNPq) for grant to M.L. Martins. and FAPESP (10/14490-1) for scholarship to S.B. Pádua.

References

1. AUSTIN B., STOBIE M., ROBERTSON PAW. *Citrobacter freundii*: the cause of gastro-enteritis leading to progressive low level mortalities in farmed rainbow trout, *Oncorhynchus mykiss* Walbaum, in Scotland. **Bull. Eur. Assoc. Fish Pathol.**, 1992, 12, 166-168.
2. BAECK GW., KIM JH., CHORESCA JR C., GOMEZ DK., SHIN SP., HAN JE., PARK SC. Mass mortality of doctor fish (*Garra rufa obtusa*) caused by *Citrobacter freundii* infection. **J. Vet. Clin.**, 2009, 26, 150-154.
3. BAI L., XIA S., LAN R., LIU L., YEC., WANG Y., JIN D., CUI Z., JING H., XIONG Y., BAI X., SUN H., ZHANG J., WANG L., XU J. Isolation and characterization of cytotoxic, aggregative *Citrobacter freundii*. **Plos One**, 2012, 7, 33054.
4. BRASIL. Ministério da Pesca e Aquicultura. Boletim estatístico da pesca e aquicultura: Brasil 2010. Brasília, DF, 2012. 129 p. in: [www.mpa.gov.br/Docs/Informacoes_e_Estatisticas/Bol etim%20Estat%20C3%ADstico%20MPA%202010.pdf](http://www.mpa.gov.br/Docs/Informacoes_e_Estatisticas/Bol_etim%20Estat%20C3%ADstico%20MPA%202010.pdf). Accessed January 30th 2013.
5. CAMPOS JL. Pintado culture in Brazil. **Global Aquac. Adv.**, 2004, 42, 42-3.
6. CHUANG YM., TSENG SP., TENG LJ., HO YC., HSUEH PR. Emergence of cefotaxime resistance in *Citrobacter freundii* causing necrotizing fasciitis and osteomyelitis. **J. Infect.**, 2006, 53, 161-163.
7. COSTA AB. **Characterization and pathological activities of *Aeromonas* bacterial complex isolated from freshwater fish**. Piracicaba, 2003, 68 p. Thesis, Universidade de São Paulo.
8. COSTA AB., CYRINO JEP. Antibiotic resistance of *Aeromonas hydrophila* isolated from *Piaractus mesopotamicus* (Holmberg, 1887) and *Oreochromis niloticus* (Linnaeus, 1758). **Sci. Agric.**, 2006, 63, 281-284.
9. EVANS JJ., KLESIUS PH., SHOEMAKER CA. First isolation and characterization of *Lactococcus garvieae* from Brazilian Nile tilapia, *Oreochromis niloticus* (L.), and pintado, *Pseudoplatystoma corruscans* (Spix & Agassiz). **J. Fish Dis.**, 2009, 32, 943-951.
10. FURUSHITA M., SHIBA T., MAEDA T., YAHATA M., KANEOKA A., TAKAHASHI Y., TORII K., HASEGAWA T., OHTA M. Similarity of tetracycline resistance genes isolated from fish farm bacteria to those from clinical isolates. **Appl. Environm. Microbiol.**, 2003, 69, 5336-5342.
11. ISHIKAWA

- MM., PÁDUA SB., SATAKE F., MARTINS ML., TAVARES-DIAS M. Identificação morfológica de organismos semelhantes à Anaplasmataceae em monócitos de surubim híbrido (*Pseudoplatystoma reticulatum* x *P. corruscans*). **Rev. Bras. Med. Vet.**, 2011, 33, 225-8.
12. JERICIC S., JAKIC-DIMIC D., VELJOVIC L. *Citrobacter freundii* as a cause of disease in fish. **Acta Vet.**, 2003, 53, 399-410.
13. KARUNASAGAR I., KARUNASAGAR I., PARI R. Systemic *Citrobacter freundii* infection in common carp, *Cyprinus carpio* L. fingerlings. **J. Fish Dis.**, 1992, 15, 95-98.
14. LÜ A., HU X., ZHENG L., ZHU A., CAO C., JIANG J. Isolation and characterization of *Citrobacter* spp. from the intestine of grass carp *Ctenopharyngodon idellus*. **Aquacult.**, 2011, 313, 156-160.
15. MAUEL MJ., MILLER DL., FRAZIER KS., HINES ME. Bacterial pathogens isolated from cultured bullfrogs (*Rana castesbeiana*). **J. Vet. Diag. Inv.**, 2002, 14, 431-433.
16. NATIONAL COMMITTEE FOR CLINICAL LABORATORY STUDIES. Performance standards for antimicrobial disk susceptibility Tests. 4 th ed. NCCLS document M2-A4. Villanova, USA, 2004.
17. NAWAZ M., KHAN AA., KHAN S., SUNG K., STEELE R. Isolation and characterization of tetracycline-resistant *Citrobacter* spp. from catfish. **Food Microbiol.**, 2008, 25, 85-91.
18. NOVAK SS., SEIGEL RA. Gram-negative septicaemia in American alligators (*Alligator mississippiensis*). **J. Wildlife Dis.**, 1986, 22, 484-487.
19. PÁDUA SB., ISHIKAWA MM., BELO MAA., JERÔNIMO GT., MARTINS ML., PELISSARI T., KASAI RYD., CARRIJO-MAUAD JR. Parasitological assessment and host-parasite relationship in farmed cachara catfish fingerlings *Pseudoplatystoma reticulatum* (Eigenmann & Eigenmann 1889). **Neotrop. Helminthol.**, 2014, 8, 37-45.
20. PILARSKI F., ROSSINI AJ., CECCARELLI PS. Isolation and characterization of *Flavobacterium columnare* (Bernardet et al. 2002) from four tropical fish species in Brazil. **Braz. J. Biol.**, 2008, 68, 409-414.
21. PRAGER HTH., TIETZE VSAFE., BOHME G. Verotoxinogenic *Citrobacter freundii* associated with severe gastroenteritis and cases of haemolytic uraemic syndrome in a nursery school: green butter as the infection source. **Epidemiol. Infect.**, 1995, 199, 441-450.
22. SATO N., YAMANE N., KAWAMURA T. Systemic *Citrobacter freundii* infection among sunfish *Mola mola* in Matsushima aquarium. **Bull. Jap. Soc. Sci. Fish.**, 1982, 49, 1551-1557.
23. SHEN JY., GU ZM., PAN XY., ZHOU BZ., YIN WL., CAO Z. Isolation and identification of *Citrobacter freundii* from *Cherax quadricarinatus*. **J. Fish. Sci. China**, 2005, 12, 197-200.
24. SILVA BC., MOURIÑO JLP., VIEIRA FN., JATOBÁ A., SEIFFERT WQ., MARTINS ML. Haemorrhagic septicaemia in the hybrid surubim (*Pseudoplatystoma corruscans* x *Pseudoplatystoma fasciatum*) caused by *Aeromonas hydrophila*. **Aquac. Res.**, 2012, 43, 908-16.
25. TAVARES-DIAS M., ISHIKAWA MM., MARTINS ML., SATAKE F., HISANO H., PÁDUA SB., JERÔNIMO GT., SANT'ANA AR. Hematologia: ferramenta para o monitoramento do estado de saúde de peixes em cultivo. In: SARAN-NETO A., MARIANO WS., POZZOBON-SORIA SF. (Org.). **Tópicos especiais em saúde e criação animal**. 1ª ed. São Carlos: Pedro & João Editores, 2009, v. 1, p. 43-80.
26. TORANZO AE., CUTRÍN JM., ROBERSON BS., NÚÑEZ S., ABELL JM., HETRICK FM., BAYA AM. Comparison of the taxonomy, serology, drug resistance transfer, and virulence of *Citrobacter freundii* strains from mammals and poikilothermic hosts. **Appl. Environm. Microbiol.**, 1994, 60, 1789-1797.