

Occurrence of *Myxobolus* spp. (Myxozoa) in the blood of *Metynnis lippincottianus* (Osteichthyes: Serrasalminidae) from eastern Amazon, Brazil

Ocorrência de *Myxobolus* spp. (Myxozoa) no sangue de *Metynnis lippincottianus* (Osteichthyes: Serrasalminidae) oriundo da Amazônia oriental, Brasil

Nyelle Priscila Brito Façanha¹; Rafaela Franco de Araújo²; Aldi Feiden²; Géssica Laila Matos da Silva³; Maria Danielle Figueiredo Guimarães Hoshino³; Eliane Tie Oba Yoshioka⁴; Marcela Nunes Videira^{3*} 

¹ Universidade Federal do Amapá – UNIFAP, Macapá, AM, Brasil

² Universidade Estadual do Oeste do Paraná – UNIOESTE, Toledo, PR, Brasil

³ Universidade do Estado do Amapá – UEAP, Macapá, AP, Brasil

⁴ Empresa Brasileira de Pesquisa Agropecuária – EMBRAPA, Macapá, AP, Brasil

How to cite: Façanha NPB, Araújo RF, Feiden A, Silva GLM, Hoshino MDFG, Yoshioka ETO, et al. Occurrence of *Myxobolus* spp. (Myxozoa) in the blood of *Metynnis lippincottianus* (Osteichthyes: Serrasalminidae) from eastern Amazon, Brazil. *Braz J Vet Parasitol* 2024; 33(2): e016123. <https://doi.org/10.1590/S1984-29612024022>

Abstract

Myxozoans are obligatory parasites and can be found in various organs and bloodstreams of fish, thus, the objective of this work was to describe the occurrence of *Myxobolus* spp. in the circulating blood of *Metynnis lippincottianus* from River Curiaú, Macapá City, eastern Amazon, Brazil. The samples of *M. lippincottianus* (11) were caught using cast net and gillnets. The fish blood was collected by puncturing the caudal vessel, using needles and syringes containing 10% of EDTA solution. Blood smear were prepared and panchromatic stained with a combination of May Grunwald-Giemsa-Wright, for observation and examination of the parasitic structures in optical microscope. Tissues from the kidney was examined using specific stereoscopic binoculars to check for the presence of cysts, lesions and parasites. The prevalence of *Myxobolus* spp. infecting the circulating blood of the fish was 36.36% (4/11) and 15 spores of mixosporidys were visualized. *Myxobolus* spp. had a prevalence of 54.55% (6/11) in host's kidney tissue and the morphometric spores data converge with observed in the blood. The morphological characteristics of the spores in the blood samples revealed two morphotypes of *Myxobolus* spp. This is the sixth occurrence recorded of *Myxobolus* spp. infecting fish blood in Brazil.

Keywords: Fish, Serrasalminidae, hemoparasite, Myxosporidia.

Resumo

Mixozoários são parasitos obrigatórios e podem ser encontrados em diversos órgãos e corrente sanguínea dos peixes. Objetivou-se neste trabalho descrever a ocorrência de *Myxobolus* spp. no sangue circulante de *Metynnis lippincottianus*, oriundo do rio Curiaú, cidade de Macapá, Amazônia Oriental, Brasil. Os exemplares de *M. lippincottianus* (n=11) foram capturados, usando-se tarrafas e redes de emalhar. O sangue de cada peixe foi coletado por punção do vaso caudal, com o auxílio de agulhas e seringas contendo EDTA 10%. Após, realizaram-se extensões sanguíneas e coloração pancromática com May Grünwald-Giemsa-Wright, para a observação e exame das estruturas parasitárias em microscópio óptico. Tecidos do rim foram examinados, utilizando-se estereomicroscópio binocular para checar a presença de cistos, lesões e parasitos. A prevalência de *Myxobolus* spp., infectando o sangue circulante dos peixes, foi de 36,36% (4/11), e um total de 15 esporos de mixosporídeos foram visualizados. *Myxobolus* spp. teve prevalência de 54,55% (6/11) no tecido renal do hospedeiro, e os dados morfométricos dos esporos convergem com os observados no sangue. As características morfológicas dos esporos, nas amostras de sangue evidenciaram dois morfotipos de *Myxobolus* spp. Esse é o sexto registro de ocorrência de *Myxobolus* spp. infectando o sangue de peixes no Brasil.

Palavras-chave: Peixe, Serrasalminidae, hemoparasito, Myxosporidia.

Received November 28, 2023. Accepted March 15, 2024.

*Corresponding author: Marcela Nunes Videira. E-mail: videiravet@gmail.com



This is an Open Access article distributed under the terms of the Creative Commons Attribution License, which permits unrestricted use, distribution, and reproduction in any medium, provided the original work is properly cited.

Introduction

Parasitism in fish is a common phenomenon in natural and farmed aquatic environments, where various species of parasites can infect and affect the health of their hosts. These parasites can be found in various parts of the fish body, such as the gills, muscles, skin, intestines, liver, and blood, where they can cause various diseases. Some parasites can infect a wide range of hosts whereas others are specific to both the species of fish and the body tissues infected (Molnár, 2002; Sitjà-Bobadilla, 2008; Ferreira et al., 2021).

Metynnis lippincottianus Cope, 1870, is a freshwater pelagic fish, with a wide distribution in South American water systems, including the drainages of French Guiana, the basins of the lower and middle Amazon and the drainages of northeastern Brazil (Zarske & Géry, 1999; Froese & Pauly, 2023). Popularly known as “pratinha”, “pacu,” and “pacu-redondo”, *M. lippincottianus* has a generalist feeding behavior, with a diet based on filamentous algae, terrestrial and aquatic plants, detritus, microcrustaceans and ostracod molluscs (Hoshino & Tavares-Dias, 2014; Kliemann et al., 2022), and it belongs to the Serrasalminidae family, which is important in the Brazilian aquarium trade as ornamental fish, as well as part of the diet of riverside populations in the Amazon region (Moreira et al., 2009; Yamada et al., 2012).

Fish like *M. lippincottianus* can host distinct species of parasites, such as the *Myxobolus* genus, which has the greatest number of species. Some species of this genus are known to be pathogenic, causing specific diseases in fry of regional and exotic fish species, including “whirling disease” in salmonids and myxobolosis in certain round fish (Steinbach Elwell et al., 2009). The clinical signs can vary according to the fish species host and the location of infection (Békési et al., 2002; Oliveira et al., 2021; Capodifoglio et al., 2019).

This type of infection can cause various problems for the host fish, and the clinical signs can compromise their health and well-being. Another associated problem is parasite transmission to other fish species or even adaptation to new infection sites. This can cause pathologies, lack of infection control, and spread of infection, increasing the risk of parasitic disease outbreaks in fish populations, causing greater problems and even an imbalance in host-linked biodiversity (Santos et al., 2013; Farias et al., 2021). Thus, fish parasitology is an important area of study for understanding the epidemiology of parasitic infections in fish, as well as for developing strategies to prevent and control parasitic diseases in aquatic environments.

In Brazil, studies about the occurrence of myxozoans infecting the blood of fish have been carried out in several regions (Central-West and North), with spores (myxospore phase) of the genus *Myxobolus* being the most common (Paperna & Di Cave, 2001; Maciel et al., 2011; Ungari et al., 2021). Also, *Sphaerospora* sp. were identified as parasitizing Amazonian fish. In Europe and Asia, other parasites of the genus *Chloromyxum*, *Myxobolus* and *Sphaerospora* have been detected in the kidney and blood of fish (Yang et al., 2022; Holzer et al., 2006; Baska & Molnar, 1988; Lom et al., 1985).

In order to contribute to information on hemoparasitism linked *Myxobolus* species in Amazonian fish, this study aimed to describe the occurrence of two morphotypes of this parasite in the circulating blood of *M. lippincottianus* (Osteichthyes: Serrasalminidae) from the Curiaú River, Macapá, Amapá, Eastern Amazon, Brazil.

Material and Methods

Collection and transportation of biological material

Metynnis lippincottianus (n = 11) specimens were collected from the Curiaú River Environmental Protection Area (APA do Rio Curiaú) (0°8'43.6" N, 51°2'30.3" W) (Figure 1). The Curiaú River APA covers the Curiaú River basin, which has an area of approximately 584.47 km², a drainage system interconnected by intermittent and perennial lakes, and the influence of the tidal and rainfall regime (Brito et al., 2022).

The fish were caught using cast net and gillnets with varying mesh sizes, to obtain a significant sample of individuals with different sizes and body weights. The fish were placed in plastic bags containing water from their own habitat, aerated using battery-operated aerators. The animals were then transported alive to the Laboratory of Morphophysiology and Animal Health - LABMORSA / UEAP, Macapá, AP.

Parasitological analysis

In the laboratory, the animals were kept in aquariums with constant aeration until further analyses. A blood sample was collected from each specimen by puncturing the caudal vessel using needles and syringes containing 10% EDTA. Blood smears and panchromatic staining with May Grünwald-Giemsa-Wright (Ranzani-Paiva et al., 2013)

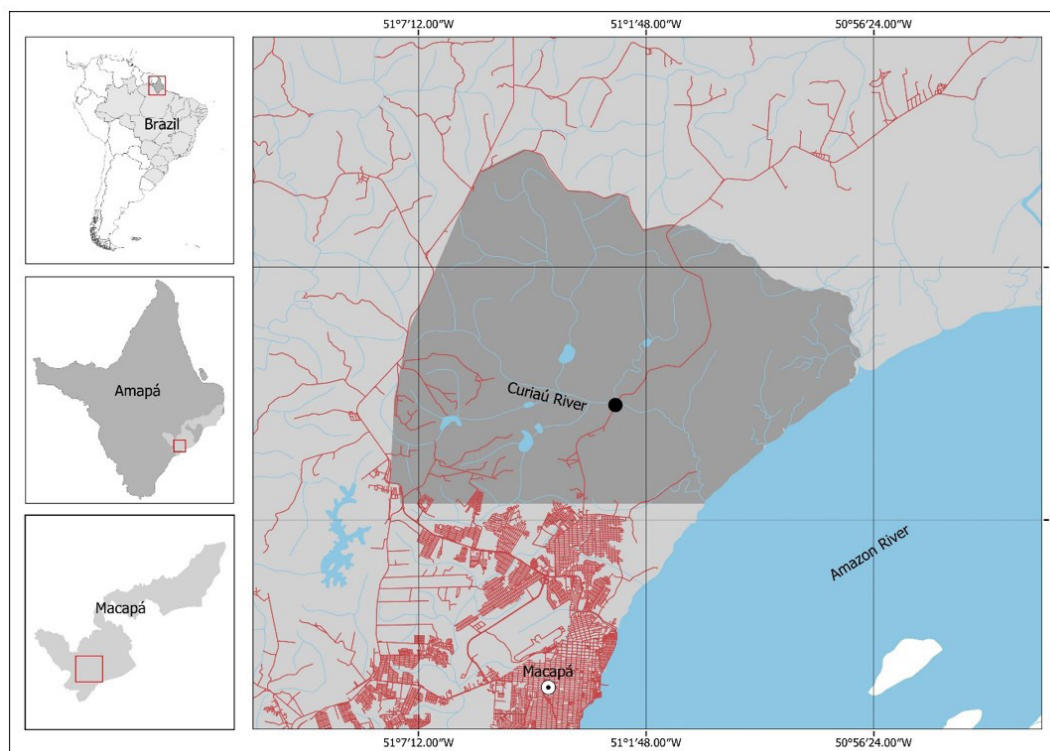


Figure 1. Brazil map with Amapá state, highlighting the Curiaú River Environmental Protection Area and its hydrography (gray line). The dot indicates the location where *Metynnis lippincottianus* specimens were captured.

were performed to observe the parasite structures. The samples were examined for hemoparasites under an optical microscope (Lumen LM3100) at 40x and 100x magnification and identified as described by Lom & Dyková (2006).

The fishes were anesthetized using tricaine methanesulfonate (MS-222), followed by euthanasia with neural myelotomy, necropsy and macroscopic observation of the kidney tissues, to check for the presence of cysts, lesions and parasites. During the necropsy, kidney fragments were visualized fresh between slides and coverslips, tissues with cysts were collected and analyzed by optical microscopy.

Parasite spores were recorded using a Moticam 2300 3.0 M camera with Motic images Plus 2.0 software attached to the microscope. The morphometric data of mature and fresh spores were obtained (μm) according to Matos et al. (2001) and analyzed as recommended by Lom & Arthur (1989).

Results and Discussion

The *M. lippincottianus* specimens were 7.94 ± 0.54 cm in total length and 11.18 ± 1.54 g in body weight. The prevalence of *Myxobolus* spp. infecting the circulating blood of the fish collected in the Curiaú River was 36.36% (4/11) and 15 hemoparasites were found. *Myxobolus* spp. had a prevalence of 54.55% (6/11) in host's kidney tissue. However, clinical signs of infection, common to the genus, could not be observed in the parasitized fish.

Metynnis lippincottianus is a freshwater pelagic fish with a diversity of ectoparasites and endoparasites (Hoshino & Tavares-Dias, 2014), such as those of the subphylum Myxozoa. *Myxobolus* is a genus of the family Myxobolidae, belonging to the phylum Cnidaria and class Myxosporea, which has the largest number of members, with more than 900 species described in literature (Eiras et al., 2021). In this study, the myxospores had two pyriform polar capsules of equal size, bilateral symmetry, and binucleate sporoplasm, indicating that the identified parasites belonged to the genus *Myxobolus* (Figure 2).

The morphometric survey revealed two morphotypes of *Myxobolus* spp., one elongated in the shape of a drop (M1) and the other oval (M2) (Figure 3). The M1 parasites measured 17.00 ± 1.49 μm in spore length and 6.00 ± 0.61 μm in width; the polar capsules present the same size with 15.00 ± 1.13 μm long and 2.40 ± 0.37 μm wide, with 16 to 18 turns of the polar filament (Figure 3A). The M2 spores were on average 11.01 ± 0.07 μm long and

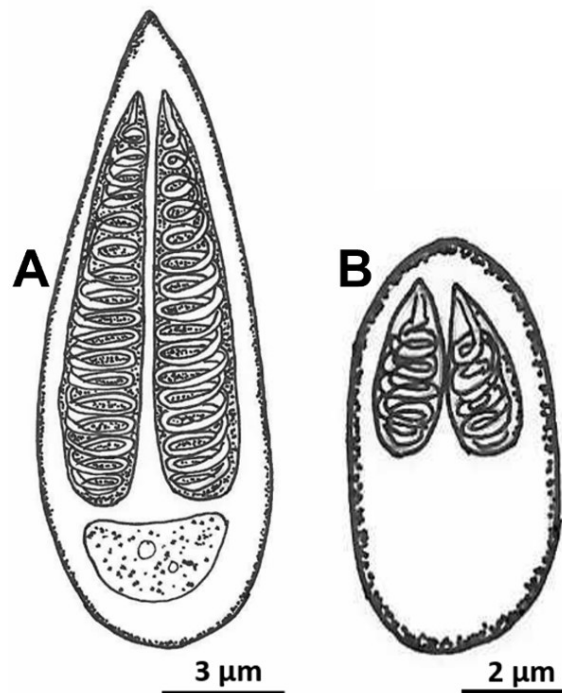


Figure 2. Illustrative drawings of the two *Myxobolus* spp. morphotypes: (A) drop-shaped; (B) oval-shaped. Hemoparasites in valve view.

$4.08 \pm 0.30 \mu\text{m}$ wide; the polar capsules present the same size and with $6.53 \pm 0.41 \mu\text{m}$ long and $1.56 \pm 0.21 \mu\text{m}$ wide, with 4 to 6 turns of the polar filament (Figure 3B).

The drop-shaped spores showed morphological characteristics similar to those of the *Myxobolus maculatus* found parasitizing the kidney of the Amazonian fish, *Metynnis maculatus* (Casal et al., 2002) (Table 1). In this study, we could not determine the species level of *Myxobolus* spp. because, in addition to methods based on morphology, morphometry, and biology (location in host tissue, morphology of sporogonic stages, and other developmental stages), use of precision devices, such as molecular tools was needed (Holzer et al., 2010; Fujimoto et al., 2013).

This group of parasites has an indirect and complex life cycle for two hosts, invertebrates, such as aquatic annelids, and intermediate vertebrates, mainly fish (Eszterbauer et al., 2015). Generally, the species of genus *Myxobolus* are morphologically characterized by their pyriform shape and presence of spores in their life cycle; they can be differentiated by the size of their polar capsules, number of polar filament turns, sporoplasm formation and valve formation (Lom & Arthur 1989; Fiala et al., 2015; De Araujo et al., 2018).

Further, organisms of the genus *Myxobolus* have two polar capsules, which originate from cells found inside the spore. The polar filaments have a helical shape and sporoplasm with a binucleate cell; the number of turns of the polar filament is important for characterizing and identifying the species. This cell contains several electrodense vesicles known as sporoplasmosomes (Casal et al., 2006).

In the Brazilian Amazon, the presence of myxosporidians has been recorded in *M. lippincottianus*, which the presence of *Henneguya* sp. has been reported and two morphotypes of *Myxobolus* sp. in the gills of this host (Carvalho et al., 2019). In work carried out by Carvalho et al. (2020), the presence of *Henneguya* sp. in 80% of the gills of *M. lippincottianus* caused hyperplasia and fusion of the gill lamellae. Both studies were carried out in the same collection area as this research.

In Brazil, only five records of *Myxobolus* spp. were reported in the fish blood (Table 2), and this work is the first record of the occurrence of *Myxobolus* spp. parasitizing the blood of *M. lippincottianus*. It is worth mentioning that this species of myxozoan has already been found in several fish organs, such as gills, blood vessels and caudal kidney (Cirkovic et al., 2010; Mabika et al., 2016; Manrique et al., 2017; Batueva, 2020; Maftuch et al., 2021; Silva et al., 2023), with the bloodstream being the least recurrent organ for *Myxobolus* sp. parasitism, which demonstrates the degree of relevance of this work.

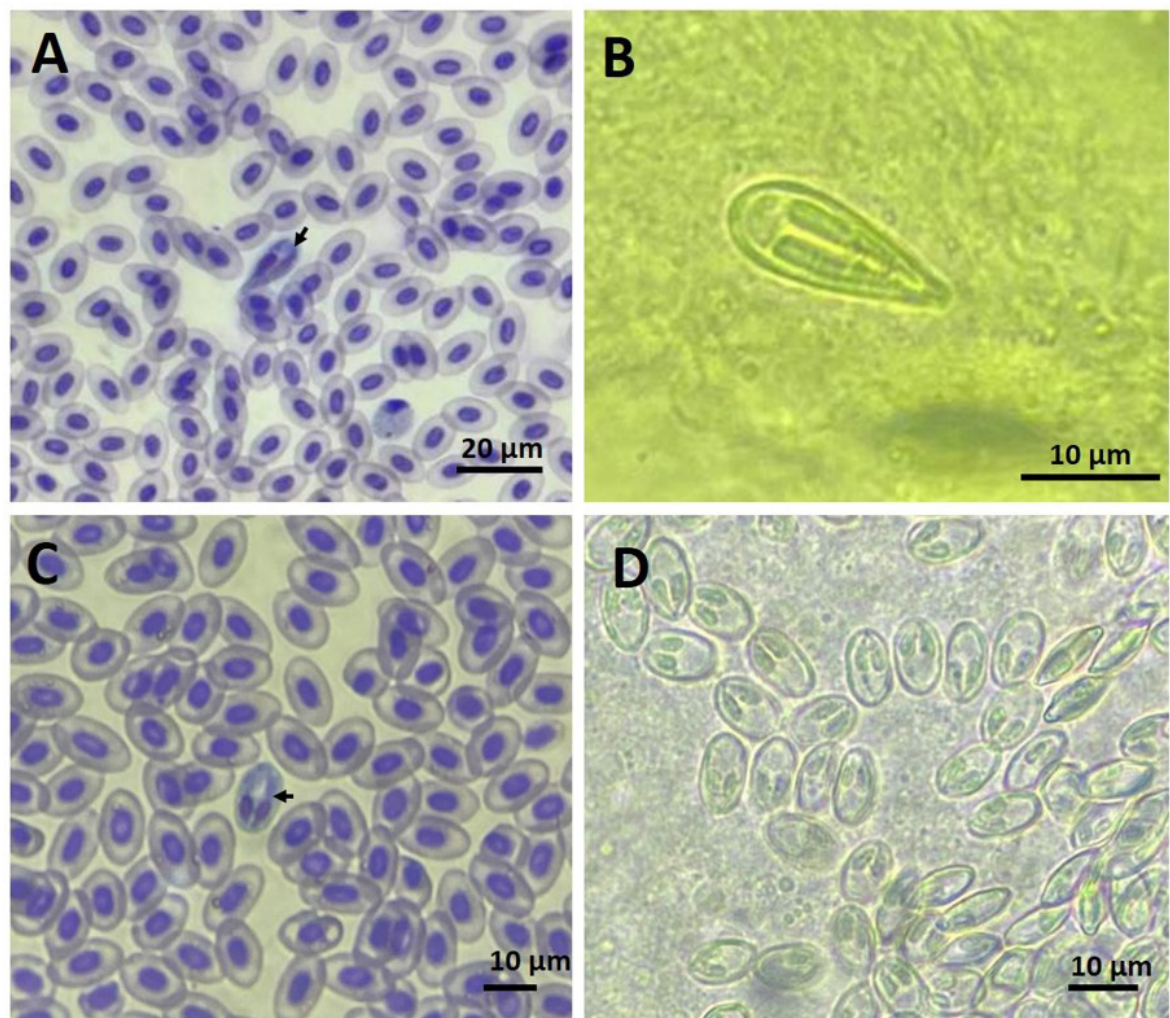


Figure 3. Photomicrograph of fresh *Myxobolus* spp. spores infecting *Metynnis lippincottianus* from the Curiaú River Environmental Protection Area, Amapá State, Eastern Amazon, Brazil. (A) and (B) Drop-shaped morphotype of *Myxobolus* spp. observed: (A) in the circulating blood (arrow); and (B) in the kidneys; (C) and (D) Oval-shaped morphotype of *Myxobolus* spp.: (C) in the blood (arrow); and (D) in the kidneys.

Table 1. Comparative measurements of *Myxobolus* spp. in *Metynnis lippincottianus* with other serrasalmids species of Brazil.

| Parasite | Spore length | Spore width | Polar capsule length | Polar capsule width | Polar filament (number of coils) | References |
|----------------------------|------------------|---------------|----------------------|---------------------|----------------------------------|------------------------|
| <i>Myxobolus maculatus</i> | 21.0 (9.7-23.0) | 8.9 (7.9-9.5) | 12.7 (11.8-13.8) | 3.2 (3.0-3.6) | 14-15 | Casal et al. (2002) |
| <i>M. metynnis</i> | 12.9-13.5 | 7.5-8.3 | 5.0-5.5 | 5.0-5.5 | 8-9 | Casal et al. (2006) |
| <i>M. colossomatis</i> | 11.8 (11.4-12.2) | 6.9 (6.6-7.2) | 6.0 (5.8-6.6) | 6.0 (5.8-6.6) | 7-8 | Molnár & Békési (1993) |
| <i>M. colossomatis</i> | 9.6 (9.1-10.28) | 5.0 (4.6-5.1) | 5.5 (4.9-6.3) | 1.6 (1.3-1.7) | - | Maciel et al. (2011) |
| <i>Myxobolus</i> sp. | 9.87 (8.9-9.8) | 6.3 (5.4-6.7) | 4.0 (4.3-5.31) | 2.4 (2.0-2.9) | - | Úngari et al. (2021) |
| <i>Myxobolus</i> sp1. | 17.0 (15.5-18.4) | 6.0 (5.4-6.6) | 15.0 (13.9-16.1) | 2.4 (2.0-2.6) | 16-18 | Present study |
| <i>Myxobolus</i> sp2. | 11.0 (11.1-11.4) | 4.1 (3.8-4.4) | 6.5 (6.1-6.9) | 1.6 (1.4-1.8) | 4-6 | Present study |

According to Holzer et al. (2006), the presence of myxosporeans may be related to the use of blood as a means of transportation and a channel for parasite proliferation in the target organs, the kidney and the gall bladder, thus demonstrating a possible justification for the evidence obtained in this study. Maciel et al. (2011), state that blood samples from fish must be evaluated to report the presence of myxozoans, since in their study the possibility of blood contamination due to the presence of this parasite, whether in the form of plasmodium, free spores in the mucosa, epithelium or connective tissues that were accessed during the puncture of the caudal vein.

Table 2. Occurrence of Myxozoa parasites in fish blood; *Myxobolus* sp1.: drop-shaped; *Myxobolus* sp2.: oval-shaped.

| Host | Family | Parasite | Infection site | Collection site | References |
|------------------------------------------------------------------------------------------------------------------------------------------------------------------------------------|-----------------------------------------------------|------------------------------------------------------------------------------------------------------------------------------------------|-----------------------------------------------------------------------------------------------------|-------------------------------|--------------------------|
| <i>Carassius auratus</i> | Cyprinidae | <i>Myxobolus honghuensis</i> | Pharynx, pseudo branch, gill, brain, head kidney, kidney, liver, spleen, ovary, intestine and blood | Jiangsu, China | Yang et al. (2022) |
| <i>Tetragonopterus araguaiensis</i> ; <i>Mylopius rubripinnis</i> ; <i>Pygocentrus nattereri</i> | Characidae; Serrasalmididae; Serrasalmididae; | <i>Myxobolus</i> spp. | Blood | Goiás and Mato Grosso, Brazil | Úngari et al. (2021) |
| <i>Colossoma macropomum</i> | Serrasalmididae | <i>Myxobolus colossomatis</i> | Blood | Amazonas, Brazil | Maciel et al. (2011) |
| <i>Salmo trutta</i> | Salmonidae | <i>Chloromyxum schurovi</i> ; <i>Chloromyxum truttae</i> ; <i>Tetracapsuloides bryosalmonae</i> and <i>Sphaerospora truttae</i> | Gills, renal tubules, gall bladder, brain, heart and blood | Scotland, United Kingdom | Holzer et al. (2006) |
| <i>Baryancistrus</i> sp. | Loricariidae | <i>Sphaerospora</i> sp. | Renal tubules and blood | Amazonas, Brazil | Paperna & Di Cave (2001) |
| <i>Alburnus alburnus</i> ; <i>Leuciscus aspius</i> ; <i>Blicca bjoerkna</i> ; <i>Abramis ballerus</i> ; <i>Rutilus rutilus</i> ; <i>Scardinius erythrophthalmus</i> | Cyprinidae | <i>Sphaerospora</i> spp. | Kidney and blood | Hungary | Baska & Molnar (1988) |
| <i>Rutilus rutilus</i> ; <i>Gobio gobio</i> ; <i>Tinca tinca</i> | Cyprinidae | <i>Sphaerospora</i> sp. | Kidney and blood | Prague, Czechoslovakia | Lom et al. (1985) |
| <i>Metynnis lippincottianus</i> | Serrasalmididae | <i>Myxobolus</i> sp1. and <i>Myxobolus</i> sp2. | Kidney and blood | Amapá, Brazil | Present study |

In this study, spores of *Myxobolus* spp. were identified in the fresh caudal kidney, and the morphometric data of the spores found in the blood converge with those observed in the kidney. The spores of *Myxobolus* spp. develop in the internal organs from where mature myxospores are transported via the bloodstream to reach the target organ, caudal kidney (Molnár et al., 2009; Bjork & Bartholomew, 2010 and Manrique et al., 2017). The observed results reinforce the hypothesis that *Myxobolus* spp. complete their sporogonic development or with release into the environment from the host urine. Sipos et al. (2018) proved through experimental results that *Myxobolus cerebralis* is found in blood during the initial stage of host infection, and that the intensity of infection in the blood decreases over time and with the growth phase.

Detailed studies on the morphology of *Myxobolus* spp. are important for understanding the biology and epidemiology of these parasites, as well as for developing effective diagnostic and treatment methods in cases of parasite outbreaks. Further, the morphology of spores, polar capsules and the number of valves can provide valuable information for identifying and characterizing different *Myxobolus* species that affect fish in the Amazon region.

The results obtained and compared with the literature demonstrated in this study allowed us to conclude that *Myxobolus* spp. are parasites of *M. lippincottianus* (Osteichthyes: Serrasalmididae) originating from the Curiaú River and although the fishes analyzed were apparently healthy, studies like this are sound, they are essential to protect the health and survival of fish populations and to maintain the health of aquatic ecosystems as a whole. So, considering the relevance and importance of this study, further research is needed to obtain more information on the life cycle in this intermediate host and the epidemiological potential linked to the infection of *Myxobolus* spp. in the circulating blood and kidney of *M. lippincottianus*.

Acknowledgements

Our sincerest thanks to the artisanal fishers and other workers who contributed for the enrichment of this research. We also thank the Coordination for the enhancement of higher education personnel, for conceding

the Masters Degree scholarship, in which has been developing a key role for the expansion and consolidation of Science in Brazil. Special thanks to the University of the State of Amapá for the financial support given to research projects associated to groups (PROGRUPOS).

Ethics declaration

The collections were approved by the Ethics Committee for the Use of Animals of the Brazilian Agricultural Research Corporation - Amapá (EMBRAPA nº12/2018) and registered with the Biodiversity Authorization and Information System (SISBIO/ICMBIO License 50376-1).

Conflict of interest

No potential conflict of interest was reported by the authors.

References

- Araújo RS, Corrêa F, Sousa FB, Ramos ABMA, Sindeaux JL No, Matos ER. Ocorrência de *Myxobolus* sp. (MYXOZOA) em *Thoracocharax stellatus* (KNER, 1858) (CHARACIFORMES) em um Igarapé da Floresta Amazônica, Pará, Brasil. *Braz J Aquat Sci Tech* 2018; 21(1): 16-20. <http://doi.org/10.14210/bjast.v21n1.11102>.
- Baska F, Molnár K. Blood stages of *Sphaerospora* spp. (Myxosporea) in cyprinid fishes. *Dis Aquat Organ* 1988; 5: 23-28. <http://doi.org/10.3354/dao005023>.
- Batueva MD. Morphological, histological, and molecular aspects of *Myxobolus zaikae* n. sp., a parasite of the roach *Rutilus rutilus*, in Lake Baikal. *Dis Aquat Organ* 2020; 142: 75-82. <http://doi.org/10.3354/dao03534>. PMID:33210614.
- Békési L, Székely C, Molnár K. Atuais conhecimentos sobre Myxosporea (Myxozoa), parasitas de peixes: um estágio alternativo dos parasitas no Brasil. *Braz J Vet Res Anim Sci* 2002; 39(5): 271-276. <http://doi.org/10.1590/S1413-95962002000500010>.
- Bjork SJ, Bartholomew JL. Invasion of *Ceratomyxa shasta* (Myxozoa) and comparison of migration to the intestine between susceptible and resistant fish hosts. *Int J Parasitol* 2010; 40(9): 1087-1095. <http://doi.org/10.1016/j.ijpara.2010.03.005>. PMID:20385137.
- Brito DMC, Bastos AB, Bastos CMC. Área de Proteção Ambiental do Rio Curiaú em Macapá/AP: territórios de resistência e a legalização de áreas. *Geo UERJ* 2022; 40(40): e64988. <http://doi.org/10.12957/geouerj.2022.64988>.
- Capodifoglio KRH, Adriano EA, Silva MRM, Maia AAM. The resolution of the taxonomic dilemma of *Myxobolus colossomatis* and description of two novel myxosporeans species of *Colossoma macropomum* from Amazon basin. *Acta Trop* 2019; 191: 17-23. <http://doi.org/10.1016/j.actatropica.2018.12.026>. PMID:30579809.
- Carvalho AA, Ferreira RLS, Araújo PG, Negrão MCS, Videira MN. Multiparasitism in gills of *Metynnis lippincottianus* from the environmental protection area of Curiaú river, Eastern Amazon. *Cienc Rural* 2019; 49(06): e20190028. <http://doi.org/10.1590/0103-8478cr20190028>.
- Carvalho AA, Videira MN, Bittencourt LS, Araújo PG, Ferreira RLS, Tavares JC, et al. Infection of *Henneguya* sp. on the gills of *Metynnis lippincottianus* from Curiaú River, in eastern Amazon region (Brazil). *Rev Bras Parasitol Vet* 2020; 29(3): e003320. <http://doi.org/10.1590/s1984-29612020037>. PMID:32667503.
- Casal G, Matos ER, Azevedo C. A new myxozoan parasite from the Amazonian fish *Metynnis argenteus* (Teleostei, Characidae): light and electron microscope observations. *J Parasitol* 2006; 92(4): 817-821. <http://doi.org/10.1645/GE-750R.1>. PMID:16995400.
- Casal G, Matos ER, Azevedo C. Ultrastructural data on the spore of *Myxobolus maculatus* n. sp. (Phylum Myxozoa), parasite from the Amazonian fish *Metynnis maculatus* (Teleostei). DAO -. *Dis Aquat Organ* 2002; 51(2): 107-112. <http://doi.org/10.3354/dao051107>. PMID:12363082.
- Cirkovic M, Milosevic N, Markovic M, Potkonjak A. Brain myxoboliasis of common carp. *Bulg J Agric Sci* 2010; 16(3): 263-265.
- Eiras JC, Cruz CF, Saraiva A, Adriano EA. Synopsis of the species of *Myxobolus* (Cnidaria, Myxozoa, Myxosporea) described between 2014 and 2020. *Folia Parasitol* 2021; 68: 12. <http://doi.org/10.14411/fp.2021.012>. PMID:34152289.
- Eszterbauer E, Atkinson S, Diamant A, Morris D, El-Matbouli M, Hartikainen H. Myxozoan life cycles: practical approaches and insights. In: Okamura B, Gruhl A, Bartholomew J, editors. *Myxozoan evolution, ecology and development*. Cham: Springer; 2015. p. 175-178. http://doi.org/10.1007/978-3-319-14753-6_10.
- Farias THV, Pala G, Araújo LRS. Parasitas de peixes com potencial zoonótico descritos no Brasil. *Ars Vet* 2021; 37(4): 211-224. <http://doi.org/10.15361/2175-0106.2021v37n4p211-224>.

- Ferreira RLS, Pinheiro AP, Dias AJS, Carvalho AA, Matos ER, Silva GA, et al. Carga parasitária x estresse oxidativo em *Satanoperca jurupari* (Heckel, 1840) na Amazônia Oriental. *Rev Ibero Americana de Ciências Ambientais* 2021; 12(3): 136-144. <http://doi.org/10.6008/CBPC2179-6858.2021.003.0013>.
- Fiala I, Bartošová-Sojková P, Whipps CM. Classification and phylogenetics of Myxozoa. In: Okamura B, Gruhl A, Bartholomew J, editors. *Myxozoan evolution, ecology and development*. Cham: Springer; 2015. p. 85-110. http://doi.org/10.1007/978-3-319-14753-6_5.
- Froese R, Pauly D. *FishBase* [online]. 2023 [cited 2023 May 10]. Available from: <http://www.fishbase.org>
- Fujimoto RY, Neves MS, Santos RFB, Souza NS, Couto MVS, Lopes JNS, et al. Morphological and hematological studies of *Trypanosoma* spp. infecting ornamental armored catfish from Guamã River-PA, Brazil. *An Acad Bras Cienc* 2013; 85(3): 1149-1156. <http://doi.org/10.1590/S0001-37652013005000039>. PMID:23903566.
- Holzer AS, Sommerville C, Wootten R. Molecular studies on the seasonal occurrence and development of five myxozoans in farmed *Salmo trutta* L. *Parasitology* 2006; 132(Pt 2): 193-205. <http://doi.org/10.1017/S0031182005008917>. PMID:16216135.
- Holzer AS, Wootten R, Sommerville C. *Zschokkella hildae* Auerbach, 1910: phylogenetic position, morphology, and location in cultured Atlantic cod. *Parasitol Int* 2010; 59(2): 133-140. <http://doi.org/10.1016/j.parint.2009.12.004>. PMID:20026425.
- Hoshino MDFG, Tavares-Dias M. Ecology of parasites of *Metynnis lippincottianus* (Characiformes: Serrasalminidae) from the eastern Amazon region, Macapá, State of Amapá, Brazil. *Acta Sci Biol Sci* 2014; 36(2): 249-255. <http://doi.org/10.4025/actasciobiolsci.v36i2.19876>.
- Kliemann BCK, Delariva RL, Manoel LO, Silva APS, Veríssimo-Silveira R, Ramos IP. Do cage fish farms promote interference in the trophic niche of wild fish in Neotropical Reservoir? *Fish Res* 2022; 248: 106198. <http://doi.org/10.1016/j.fishres.2021.106198>.
- Lom J, Arthur JR. A guideline for the preparation of species descriptions in Myxosporea. *J Fish Dis* 1989; 12(2): 151-156. <http://doi.org/10.1111/j.1365-2761.1989.tb00287.x>.
- Lom J, Dyková I. Myxozoan genera: definition and notes on taxonomy, life-cycle terminology and pathogenic species. *Folia Parasitol* 2006; 53(1): 1-36. <http://doi.org/10.14411/fp.2006.001>. PMID:16696428.
- Lom J, Pavlásková M, Dyková I. Notes on kidney-infecting species of the genus *Sphaerospora* Thélohan (Myxosporea), including a new species *S. gobionis* sp. Nov., and on myxosporean life cycle stages in the blood of some freshwater fish. *J Fish Dis* 1985; 8(2): 221-232. <http://doi.org/10.1111/j.1365-2761.1985.tb01217.x>.
- Mabika N, Barson M, Van Dyk C, Avenant-Oldewage A. Taxonomy, distribution and prevalence of parasites of tigerfish, *Hydrocynus vittatus* (Castelnau, 1861) in the Sanyati basin, Lake Kariba, Zimbabwe. *Acta Parasitol* 2016; 61(3): 614-620. <http://doi.org/10.1515/ap-2016-0082>. PMID:27447228.
- Maciel PO, Affonso EG, Boijink CL, Tavares-Dias M, Inoue LAKA. *Myxobolus* sp. (Myxozoa) in the circulating blood of *Colossoma macropomum* (Osteichthyes, Characidae). *Rev Bras Parasitol Vet* 2011; 20(1): 82-84. <http://doi.org/10.1590/S1984-29612011000100018>. PMID:21439240.
- Maftuch M, Wicaksono BS, Nurin FN, Sebastian A. Molecular expressions: Scanning Electron Microscope (SEM) in gills of *Cyprinus carpio* infected *Myxobolus* sp. *J Ilmiah Perikanan Dan Kelautan* 2021; 13(2): 307-312. <http://doi.org/10.20473/jipk.v13i2.25484>.
- Manrique WG, Figueiredo MAP, de Andrade Belo MA, Martins ML, Molnár K. *Myxobolus* sp. and *Henneguya* sp. (Cnidaria: Myxobolidae) natural co-infection in the kidney of *Piaractus mesopotamicus* (Characiformes: Serrasalminidae). *Parasitol Res* 2017; 116(10): 2853-2860. <http://doi.org/10.1007/s00436-017-5571-2>. PMID:28779214.
- Matos ER, Corral L, Matos P, Casal G, Azevedo C. Incidência de parasitas do Phylum Myxozoa (Sub-reino Protozoa) em peixes da região amazônica, com especial destaque para o gênero *Henneguya*. *Rev Ciênc Agrár* 2001; 36: 83-99.
- Molnár K, Békési L. Description of a new *Myxobolus* species, *M. colossomatis* n. sp. from the teleost *Colossoma macropomum* of the Amazon River basin. *J Appl Ichthyology* 1993; 9(1): 57-63. <http://doi.org/10.1111/j.1439-0426.1993.tb00388.x>.
- Molnár K, Eszterbauer E, Marton S, Cech G, Székely C. *Myxobolus erythrophthalmi* sp. n. and *Myxobolus shaharomae* sp. n. (Myxozoa: Myxobolidae) from the internal organs of rudd, *Scardinius erythrophthalmus* (L.), and bleak, *Alburnus alburnus* (L.). *J Fish Dis* 2009; 32(3): 219-231. <http://doi.org/10.1111/j.1365-2761.2008.00976.x>. PMID:19309417.
- Molnár K. Site preference of fish myxosporeans in gills. *Dis Aquat Organ* 2002; 48(3): 197-207. <http://doi.org/10.3354/dao048197>. PMID:12033706.
- Moreira LHA, Takemoto RM, Yamada FH, Ceschini TL, Pavanelli GC. Ecological aspects of metazoan endoparasites of *Metynnis lippincottianus* (Cope, 1870) (Characidae) from Upper Paraná river floodplain, Brazil. *Helminthologia* 2009; 46(4): 214-219. <http://doi.org/10.2478/s11687-009-0040-9>.

Oliveira JEF, Figueredo RTA, Sindeaux-Neto JL, Vilhena MPSP, Berrêdo JF, Matos E, et al. Hepatic coccidiosis in *Serrasalmus rhombeus* Linnaeus, 1766 from the Amazon basin: morphological and histopathological aspects. *Rev Bras Parasitol Vet* 2021; 30(1): e026120. <http://doi.org/10.1590/s1984-29612021007>. PMID:33852702.

Paperna I, Di Cave D. Kidney sphaerosporosis with extrasporogonic stages in the blood in *Baryancistrus* sp. (Loricaridae) from Amazonian Brazil. *Parasite* 2001; 8(1): 71-74. <http://doi.org/10.1051/parasite/2001081071>. PMID:11304954.

Ranzani-Paiva MJT, Pádua SB, Tavares-Dias M, Egami MI. *Métodos para análise hematológica em peixes*. Maringá: Editora UEM; 2013. <http://doi.org/10.7476/9788576286530>.

Santos EF, Tavares-Dias M, Pinheiro DA, Neves LR, Marinho RGB, Dias MKR. Fauna parasitária de tambaqui *Colossoma macropomum* (Characidae) cultivado em tanque-rede no estado do Amapá, Amazônia oriental. *Acta Amaz* 2013; 43(1): 105-111. <http://doi.org/10.1590/S0044-59672013000100013>.

Silva MF, Silva DT, Giese E, Furtado AP, Matos P, Lima AM, et al. Phylogeny and ultrastructure of *Myxobolus rangeli* n. sp. (Myxozoa, Bivalvulida), a histozoic parasite in Siluriformes fish from the Amazon region. *Rev Bras Parasitol Vet* 2023; 32(2): e005923. <http://doi.org/10.1590/s1984-29612023034>. PMID:37341287.

Sipos D, Ursu K, Dán Á, Herczeg D, Eszterbauer E. Susceptibility-related differences in the quantity of developmental stages of *Myxobolus* spp. (Myxozoa) in fish blood. *PLoS One* 2018; 13(9): e0204437. <http://doi.org/10.1371/journal.pone.0204437>. PMID:30240456.

Sitjà-Bobadilla A. Fish immune response to Myxozoan parasites. *Parasite* 2008; 15(3): 420-425. <http://doi.org/10.1051/parasite/2008153420>. PMID:18814716.

Steinbach Elwell LC, Stromberg KE, Ryce EKN, Bartholomew JL. *Whirling disease in the United States: a summary of progress in research and management 2009* [online]. Bozeman: Trout Unlimited and the Whirling Disease Foundation; 2009 [cited 2023 Jul 7]. Available from: <https://daretoprepare.com/Food/Whirling.Fish.Disease.2009.pdf>

Úngari LP, Vieira DHMD, Santos ALQ, Silva RJ, O'Dwyer LH. *Myxobolus* spp. (Cnidaria: Myxobolidae) in the circulating blood of fishes from Goiás and Mato Grosso States, Brazil: case report. *Braz J Biol* 2021; 82: e242823. <http://doi.org/10.1590/1519-6984.242823>. PMID:34133567.

Yamada FH, Moreira LHA, Ceschini TL, Lizama MLAP, Takemoto RM, Pavanelli GC. Parasitism associated with length and gonadal maturity stage of the freshwater fish *Metynnis lippincottianus* (Characidae). *Neotr Helmint* 2012; 6(2): 247-253.

Yang K, Zhai K, Xi B, Chen K, Xie J. Tissue tropism of *Myxobolus honghuensis* in diseased and asymptomatic gibel carp (*Carassius auratus gibelio*). *J Fish China* 2022; 46(6): 1085-1093.

Zarske A, Géry J. Revision der neotropischen Gattung *Metynnis* Cope, 1878. 1. Evaluation der Typusexemplare der nominellen Arten (Teleostei: Characiformes: Serrasalminidae). *Zool Abh Mus Tierk* 1999; 50(13): 169-216.