



Short communication

Assessment of luteal function in goats by ultrasonographic image attribute analysis

E.K. Arashiro^{a,*}, J.F. Fonseca^b, L.G.B. Siqueira^c, C.A. Fernandes^d, F.Z. Brandao^a, E. Oba^e, J.H. Viana^c^a Fluminense Federal University, Niteroi, RJ 24230-340, Brazil^b Embrapa Goat Research Center, Sobral, CE 62011-970, Brazil^c Embrapa Dairy Cattle Research Center, Juiz de Fora, MG 36038-330, Brazil^d University of Alfenas, Alfenas, MG 37130-000, Brazil^e São Paulo State University, Botucatu, SP 18618-000, Brazil

ARTICLE INFO

Article history:

Received 18 December 2009

Received in revised form 9 July 2010

Accepted 21 July 2010

Available online 17 August 2010

Keywords:

Corpus luteum

Echotexture

Goat

Ultrasound

ABSTRACT

The aim of this study was to evaluate the potential of luteal echotexture (mean pixel value and heterogeneity), as a tool for assessing luteal function during different phases of the estrous cycle in Toggenburg goats. Sonographic evaluations of the ovaries were performed daily in nulliparous goats ($n = 21$), using a 5 MHz linear rectal probe, commencing at estrus (day 0). Blood samples were collected daily for plasma progesterone RIA and images recorded on VHS tape and then digitized in TIFF format at a resolution of 1500×1125 pixels. A representative elementary area (REA) of 5625 pixels (0.31 cm^2) of these images was analyzed using custom-developed software, for mean pixel value and heterogeneity. Mean plasma progesterone, luteal area and pixels all reached maximum values at approximately days 13 and 14, during luteogenesis. Luteolysis was characterized by an abrupt decrease in blood progesterone concentration following ovulation, and a gradual decline in luteal area and pixel values. The luteal tissue area was positively correlated with plasma progesterone concentration during both luteogenesis ($r = 0.63$; $P < 0.05$) and luteolysis ($r = 0.50$; $P < 0.05$). Weak correlations were recorded between the mean pixel value and luteal tissue area during luteogenesis ($r = 0.34$; $P < 0.05$) and luteolysis ($r = 0.26$; $P < 0.05$). Similarly, weak correlations between the mean pixel value and plasma progesterone concentration were recorded during luteogenesis ($r = 0.24$; $P < 0.05$) and luteolysis ($r = 0.37$; $P < 0.05$). The pixel heterogeneity was not correlated with luteal tissue area or the plasma progesterone concentration at any stage of the estrous cycle. The results show the association between the corpus luteum echotexture and steroidogenic function to be weak and the present ultrasound technology, to have limited potential in evaluating luteal function in goats.

© 2010 Elsevier B.V. All rights reserved.

1. Introduction

Real-time transrectal ultrasonography (RTU) has shed light on important reproductive events, and is considered to be one of the most significant technological advances in animal reproduction research, since the introduction of radioimmunoassay (RIA) (Ginther, 1986). In small ruminants, corpora lutea (CL's) evaluation by RTU is equally as efficient as invasive techniques, such as laparotomy and

* Corresponding author at: Embrapa Dairy Cattle Research Center, Laboratory of Animal Reproduction, Rua Eugenio do Nascimento 610, Bairro Dom Bosco, Juiz de Fora, MG 36038-330, Brazil. Tel.: +55 32 3311 7438; fax: +55 32 3311 7401.

E-mail address: eduardoarashiro@hotmail.com (E.K. Arashiro).

laparoscopy (Viñoles et al., 2004; Simões et al., 2005). Thus morphometric characteristics of the CL (diameter, area or volume), as measured by RTU in association with plasma progesterone concentration, have been extensively used to evaluate CL function in large domestic animals (Veronesi et al., 2002), and only more recently in small ruminants (Gonzalez-Bulnes et al., 2000).

An ultrasonographic image is known to be composed of thousands of picture elements (pixels), that numerically represent 256 shades of gray (0 = black; 255 = white), depending on the brightness (Tom et al., 1998). The density and gross features of the tissue can be assessed by RTU. However these cannot be quantified by the human eye, which can only distinguish 18–20 different shades of gray (Pierson and Adams, 1995). The use of computer algorithms (computer-assisted analysis) permits a quantitative assessment of the intensity of each pixel present on an image, allowing an objective evaluation of the CL and thus overcoming the subjectivity of the visual analyses (Singh et al., 2003).

In the past, real-time ultrasonography has been used for the functional evaluation of different tissues, including testes, ovarian follicles and CL's. Regarding luteal function, previous studies on cows and ewes have demonstrated a relationship between the CL echotexture and the physiological changes during different phases of the estrous cycle (Davies et al., 2006; Siqueira et al., 2009). However, only a few studies have been performed using the technique of computer-assisted analysis to determine luteal function in goats (Simões et al., 2007).

The aim of the present study was to establish and validate a methodology for evaluating goat CL's by computer-assisted ultrasonographic image analysis, and to assess its ability in determining luteal function during different phases of the estrous cycle.

2. Materials and methods

2.1. Experimental design, animals and facilities

The experiment was conducted on a dairy goat farm located near the city of Coronel Pacheco, in the Minas Gerais State of Brazil (21°35'S, 43°15'W, 435 m altitude), during the onset of the natural breeding season (March and April).

Twenty-three nulliparous Toggenburg goats (*Capra hircus*), with an average age of 8 months, a mean live weight of 33.5 ± 1.2 kg and mean body condition score (BCS) of 3.5 ± 0.1 (scale of 1–5) (Suiter, 1994) were used in the trial. Two animals were removed from the experiment due to follicular cysts. All does used in the trial exhibited natural estrus during a 48-h period and were free of any reproductive abnormalities.

The does were kept as a group in a single pen and fed Napier grass (*Pennisetum purpureum* v. *Taiwan*) and a concentrate. Water and minerals were available ad lib.

2.2. Ovarian ultrasonographic evaluation

The ovarian ultrasonographic evaluations were performed daily, by the same technician, from overt estrous identification (day 0), throughout an estrous cycle (21 days) using a portable ultrasound device (Aloka SSD 500, Aloka Co, Tokyo, Japan), equipped with an adapted linear rectal 5 MHz transducer. The focus field (F1 and F2) and proximal, distal and total gains were standardized and uniform throughout the experimental observation period.

The number of ovulations was determined by the monitoring of follicles larger than 5 mm after the onset of estrus, and this was later confirmed by the number of CL's observed by ultrasound. The number and tissue area

of each CL, as well as the presence or absence of a central cavity, was also recorded. In those does with more than one ovulation, luteal tissue area was considered as the sum of the luteal area of all CL's present.

2.3. Image capture and computer-assisted analysis

The capture and image analysis procedures used were as described for cattle (Siqueira et al., 2009). Image capture was performed by coupling a video cassette recorder using a co-axial cable and recording a representative good quality frozen image on the VHS tape at the SP velocity, for approximately 10 s. Recorded images were transferred to a computer equipped with a video capture board and saved in the non-compressed Tagged Image File (TIFF) format, with a resolution of 1500×1125 pixels.

Computer analysis was performed using a custom-developed software (Quantoro®), as previously described (Siqueira et al., 2009). Briefly, the procedure consisted of the selection of a specific region on the CL, followed by software calculation of the brightness intensity of each pixel composing that area – which received a numerical value of between 0 (black) and 255 (white). Images with artifacts, or encoding fluid-filled cavities or ovarian stroma were excluded from the analyses. Luteal echotexture was represented by the mean pixel value and the standard deviation of this value (heterogeneity).

A minimum representative area (REA) was determined beforehand, based on the criteria of Van den Bygaart and Protz (1999) and modified for use in ultrasound images. In the present study, an REA of 75×75 pixels was used – which represents 5625 pixels.

2.4. Blood samples and plasma progesterone concentrations

Blood samples were collected daily via the jugular vein, using vacuum tubes containing sodium EDTA. Samples were centrifuged at $894 \times g$ for 20 min at 5 °C and the plasma samples then aspirated and stored at –20 °C in 1.5 ml tubes, until RIA plasma progesterone analyses.

Plasma progesterone concentration was determined by radioimmunoassay (RIA), using commercial RIA kits (Coat-a-Count®, Medlab) at the Endocrine Laboratory of the Veterinary Medicine and Animal Science of the São Paulo State University (UNESP), Brazil. The assay sensitivity was 0.02 ng/mL, and inter- and intra-assay variation coefficients 2.75% and 1.87%, respectively.

2.5. Statistical analyses

Outcome variables (mean pixel value and heterogeneity, luteal tissue area and plasma progesterone concentration) were evaluated for normality using the Lilliefors test, and analyzed for the main effect of time (day of the estrous cycle or hours from luteolysis). Due to the expected differences between does at the time of natural luteolysis, data were analyzed according to estrous cycle period: luteogenesis (days 0–16), and luteolysis, which was normalized to the time that plasma progesterone concentrations decreased to <1 ng/mL in each goat (–48 to +72 h from progesterone <1 ng/mL). Daily differences between means were compared using the Tukey's test. Correlations between the luteal tissue area and the mean pixel value, as well as plasma progesterone concentrations and the mean pixel value were compared using Pearson's correlation method. The SAS MIXED procedure (version 9.1.3, SAS Institute, Inc. Cary, NC) was used for the statistical analysis. A probability of $P < 0.05$ indicated that a difference was significant, and all results are presented as the mean \pm SEM.

3. Results

The luteal tissue area progressively increased ($P < 0.05$) until day 9 of the estrous cycle (1.26 ± 0.08 cm²), while no significant increase was recorded in the subsequent days. Luteal tissue area reached its maximum value on day 15 (1.65 ± 0.02 cm²). A time effect was observed regarding the plasma progesterone concentration and the levels progressively increased until day 9 ($P < 0.05$), reaching a maximum value on day 14 (8.32 ± 0.40 ng/mL) (Fig. 1). Luteolysis was characterized by an abrupt decrease in the plasma progesterone concentration, which reflected values of below 1 ng/mL, within 24 h. Luteal tissue area was positively cor-

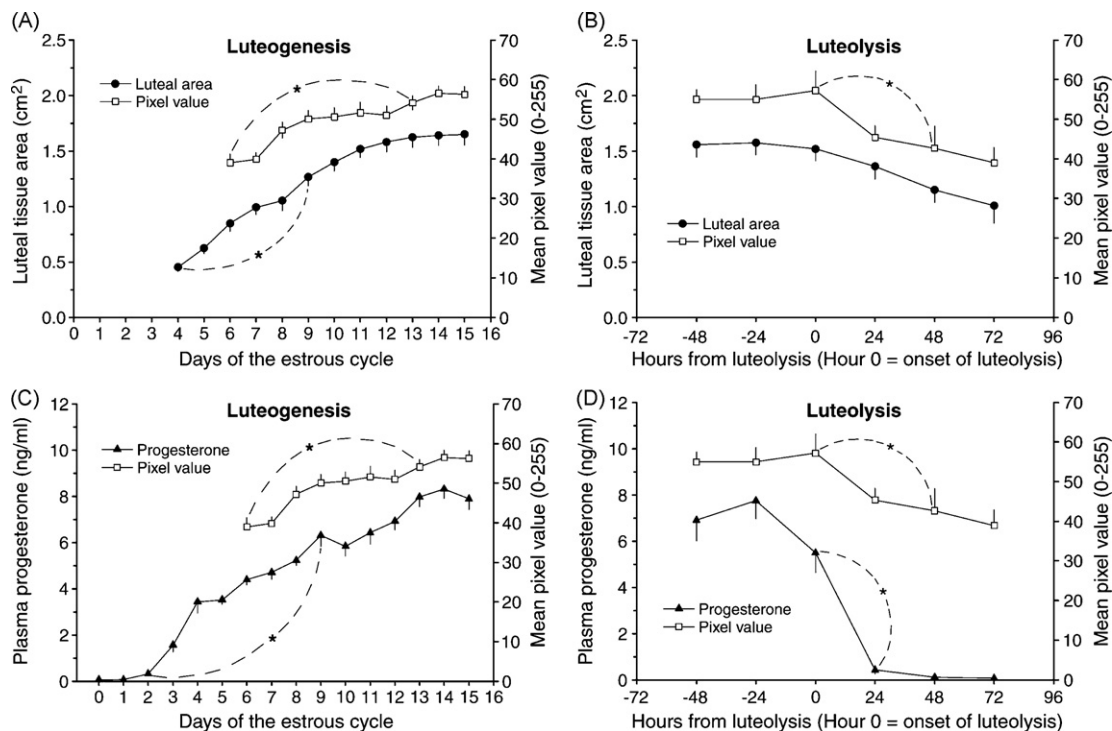


Fig. 1. Mean (\pm SEM) luteal tissue area, pixel value and plasma progesterone concentration during luteogenesis (A and C) and luteolysis (B and D) in goats.

related with the plasma progesterone concentration during both luteogenesis and luteolysis ($r=0.63$ and $r=0.50$; $P<0.05$, respectively). As expected, during luteolysis the plasma progesterone concentration decreased faster than the luteal tissue area (Fig. 1).

The mean pixel value significantly ($P<0.05$) changed throughout the estrous cycle. A progressive increase was observed until day 13 of the cycle, recording a higher value than that observed earlier in the estrous cycle. The mean pixel value decreased 48 h after the onset of luteolysis. During luteogenesis, the mean pixel value was positively correlated with the luteal tissue area ($r=0.34$; $P<0.05$), and also with the plasma progesterone concentration ($r=0.24$; $P<0.05$). These correlations were also observed during luteal regression ($r=0.26$ and $r=0.37$; $P<0.05$, respectively) (Fig. 1). Regarding the CL heterogeneity, neither a significant change, nor correlations with any parameters were recorded throughout the estrous cycle of the doe. Double ovulations were observed in 38.1% of the does (8/21), but there was no significant difference in mean pixel value or in heterogeneity between does bearing a single or double CL.

4. Discussion

Luteal dynamics are characterized by a progressive increase in the luteal tissue area during luteogenesis, followed by a plateau phase and later on, by luteolysis. This CL growth and regression pattern have been previously described in goats (Orita et al., 2000; Simões et al., 2005), and other ruminants, such as cattle (Kastelic et al., 1990; Siqueira et al., 2009) and sheep (Gonzalez-Bulnes et al.,

2000). The luteal tissue area was correlated with the plasma progesterone concentration – as the histological and biochemical changes that occur in a CL during its development, allow for the synthesis and release of progesterone. In the present experiment nulliparous does were used as the experimental model, nevertheless estrous cycle length and plasma progesterone levels were within the range previously reported for goats (Simões et al., 2005), and no precocious luteolysis occurred. Consequently, the expected correlation of luteal tissue area with progesterone concentration was recorded, following the same pattern as adult animals.

During luteolysis, a temporal difference between functional (plasma progesterone) and morphological (luteal tissue area) regression of the CL was recorded. Plasma progesterone concentration decreased faster and more abruptly than the luteal tissue area, which showed a slower and gradual decrease. This lack of synchrony has been previously reported in goats (Simões et al., 2007), cows (Viana et al., 1999) and sheep (Davies et al., 2006). Presumably, the decrease in plasma progesterone concentration occurs due to the vascular changes that occur in the CL, prior to the onset of natural or induced luteolysis (Acosta and Miyamoto, 2004), and also to changes in the enzyme system that regulates steroidogenesis (Niswender et al., 2000). Luteal morphological regression as such involves a complex process of cellular death and tissue remodeling (McCracken et al., 1999).

In the current study, luteal tissue area was related to the mean pixel values. A positive correlation was recorded for these two parameters during luteogenesis ($r=0.34$) and luteolysis ($r=0.26$). Changes in the CL mean pixel

value have been reported to reflect the hypertrophy and hyperplasia of the luteal cells during luteogenesis, with the development of a more dense and therefore more echogenic structure (Davies et al., 2006).

The mean pixel value was also consistently related to the CL functional status. The changes observed in plasma progesterone concentration were correlated with changes in the mean pixel value – increasing during luteogenesis ($r=0.24$) and decreasing during luteolysis ($r=0.37$). The results of the current study in goats are similar to previous reports in sheep ($r=0.48$ for the Western White Face breed and $r=0.26$ for the Finn breed), although in this species the mean pixel value was not considered to be reliable as a predictive measure (Davies et al., 2006).

Neither a time effect regarding CL heterogeneity, nor a significant correlation between this parameter and CL tissue area or plasma progesterone concentration was recorded. This trend was also observed in sheep (Davies et al., 2006), but not in large ruminants (Siqueira et al., 2009). Demonstrating that, despite a similar CL histological structure, image analysis procedures cannot be extrapolated between species. Pixel heterogeneity as such results from the presence of several cell types (luteal and non-luteal), thus creating areas of different echogenicity (Duggavathi et al., 2003). Therefore, heterogeneity is considered to be a parameter more related to the CL structure than CL function (Davies et al., 2006). This difference between species may result from differences in the sonographic approach to the ovaries. In large ruminants, rectal manipulation allows close proximity of the ultrasound transducer and the corpus luteum, and this is not always possible in goats or sheep, and lower quality images may have also masked the heterogeneity characteristics. Consistent with this, differences in heterogeneity have been found in ewes where ovaries were removed and analyzed in a water bath (Duggavathi et al., 2003).

Computer-assisted image analysis is a technological extension of reproductive ultrasonography (Singh et al., 2003). The results of the present study, however, showed that mean pixel value still has limited potential use as a parameter, in addition to morphometric measurements to assess luteal function. The correlations obtained in the present study may have been related to the technology used. The ongoing improvement of ultrasound technology, such as the development of better definition devices, equipped with high frequency probes (e.g. Biomicroscopy), as well as the improvement of computer algorithms with the use of lacunarity (related to the variation of pixel distribution), may turn luteal echotexture analysis into a useful diagnostic and predictive tool.

5. Conclusions

The results show that the relationship between CL echotexture and steroidogenic function is small and, with the present ultrasound technology, has limited potential as a means of evaluating luteal function in goats.

Acknowledgments

The authors thank Dr. Henrique Bruschi for providing the animals for the project. This study was financially supported by FAPEMIG (Project 2625-5.04/07), FOPESQ/PROPPi and FAPERJ. Arashiro received a Master's of Science scholarship from CAPES, Brazil.

References

- Acosta, T.J., Miyamoto, A., 2004. Vascular control of ovarian function: ovulation, corpus luteum formation and regression. *Anim. Reprod. Sci.* 82–83, 127–140.
- Davies, K.L., Bartlewski, P.M., Pierson, R.A., Rawlings, N.C., 2006. Computer assisted image analyses of corpora lutea in relation to peripheral concentrations of progesterone: a comparison between breeds of sheep with different ovulation rates. *Anim. Reprod. Sci.* 96, 165–175.
- Duggavathi, R., Bartlewski, P.M., Pierson, R.A., Rawlings, N.C., 2003. Luteogenesis in cyclic ewes: echotextural, histological, and functional correlates. *Biol. Reprod.* 69, 634–639.
- Gonzalez-Bulnes, A., Santiago-Moreno, J., Gomez-Brunet, A., Lopez-Sebastian, A., 2000. Relationship between ultrasonographic assessment of the corpus luteum and plasma progesterone concentration during the oestrous cycle in monovular ewes. *Reprod. Domest. Anim.* 35, 65–68.
- Ginther, O.J., 1986. *Ultrasonic Imaging and Reproductive Events in the Mare*. Equiservices Publishing, Cross Plains, WI.
- Kastelic, J.P., Pierson, R.A., Ginther, O.J., 1990. Ultrasonic morphology of corpora lutea and central luteal cavities during the estrous cycle and early pregnancy in heifers. *Theriogenology* 34, 487–498.
- McCracken, J.A., Custer, E.E., Lamsa, J.C., 1999. Luteolysis: a neuroendocrine-mediated event. *Physiol. Rev.* 79 (2), 263–304.
- Niswender, G.D., Juengel, L.J., Silva, P.J., Rollyson, M.K., McIntush, E.W., 2000. Mechanism controlling the function and life span of the corpus luteum. *Physiol. Rev.* 80, 1–29.
- Orita, J., Tanaka, T., Kamomae, H., Kaneda, Y., 2000. Ultrasonographic observation of follicular and luteal dynamics during the estrous cycle in Shiba goats. *J. Reprod. Dev.* 46, 31–37.
- Pierson, R.A., Adams, G.P., 1995. Computer-assisted image analysis, diagnostic ultrasonography and ovulation induction: strange bedfellows. *Theriogenology* 43, 105–112.
- Simões, J., Potes, J., Azevedo, J., Almeida, J.C., Fontes, P., Baril, G., Mascarenhas, R., 2005. Morphometry of ovarian structures by transrectal ultrasonography in Serrana goats. *Anim. Reprod. Sci.* 85, 263–273.
- Simões, J., Almeida, J.C., Valentim, R., Baril, G., Azevedo, J., Fontes, P., Mascarenhas, R., 2007. Assessment of luteal function by ultrasonographic appearance and measurement of corpora lutea in goats. *Anim. Reprod. Sci.* 97, 36–46.
- Singh, J., Adams, G.P., Pierson, R.A., 2003. Promise of new image technologies for assessing ovarian function. *Anim. Reprod. Sci.* 78, 371–399.
- Siqueira, L.G.B., Torres, C.A.A., Amorim, L.S., Souza, E.D., Camargo, L.S.A., Fernandes, C.A.C., Viana, J.H.M., 2009. Interrelationships among morphology, echotexture, and function of the bovine corpus luteum during the estrous cycle. *Anim. Reprod. Sci.* 115 (1–4), 18–28.
- Suiter, J., 1994. Body condition scoring in sheep and goats. *Farmnote* 69/94.
- Tom, J.W., Pierson, R.A., Adams, G.P., 1998. Quantitative echotexture analysis of bovine corpora lutea. *Theriogenology* 49, 1345–1352.
- Van den Bygaart, A.J., Protz, R., 1999. The representative elementary area (REA) in studies of quantitative soil micromorphology. *Geoderma* 89, 333–346.
- Veronesi, M.C., Gabai, G., Battocchio, M., Mollo, A., Soldano, F., Bono, G., Cairolì, F., 2002. Ultrasonographic appearance of tissue is a better indicator of CL function than CL diameter measurement in dairy cows. *Theriogenology* 58, 61–68.
- Viana, J.H.M., Ferreira, A.M., Sá, W.F., et al., 1999. Luteal function in Gyr cows. *Arq. Bras. Med. Vet. Zootec.* 1 (3), 257–262.
- Viñoles, C., Meikle, A., Forsberg, M., 2004. Accuracy of evaluation of ovarian structures by transrectal ultrasonography in ewes. *Anim. Reprod. Sci.* 80, 69–79.